

Clinica Ortopedica e
Traumatologica
Università degli Studi di Pavia

Fondazione
IRCCS Policlinico
San Matteo

Chairman: Prof. F. Benazzo



Inside-out meniscal repair: How I do
F. Benazzo

5th Advanced Course on
Knee Surgery

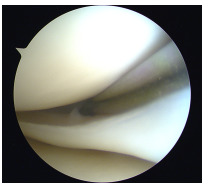


Key Points

- Meniscal Tears to be fixed
- Inside-out: still valid option?
- The tools
- The technique
 - Medial meniscus
 - Lateral meniscus
- Conclusions

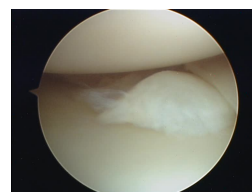
Meniscal tears: which ones do I repair?

- Longitudinal tears in the red-red zone
- Tears >1 cm
- Associated to ACL reconstruction
- Bucket handle in < 16 years old
- (No older than 6 weeks)
- Lateral meniscus: I dare more



And which ones I do not repair?

- Tears in the white zone
- Radial tears
- Flap tears
- Degenerative tears
- Incomplete tears
- Tears in > 30 years old, even in conjunction with ACL-R



Inside-out suture

- Originally described by Henning in 1980
- For years considered “the gold standard”
- More than 80% of success rate

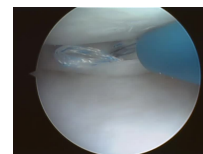
~~How I do?~~

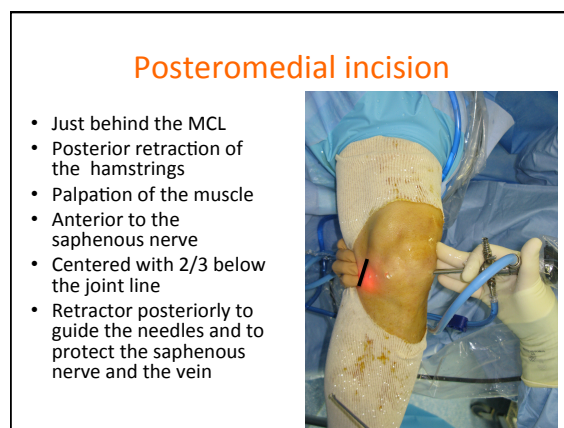
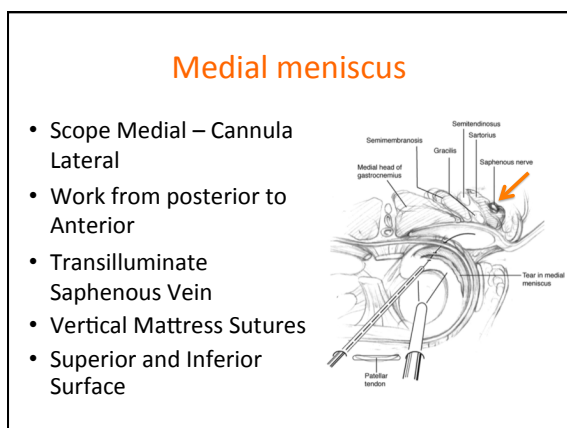
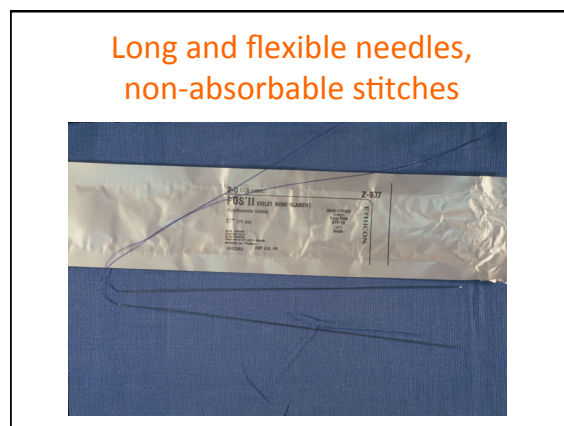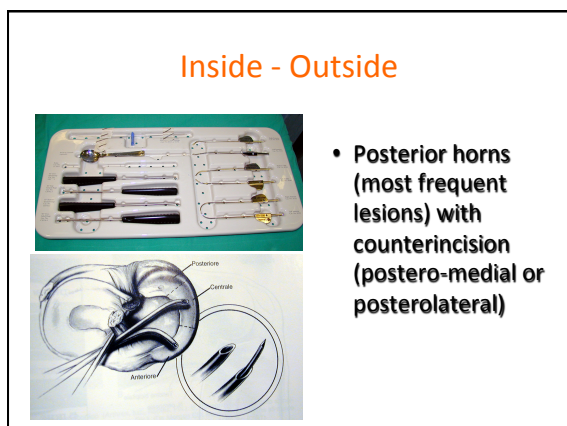
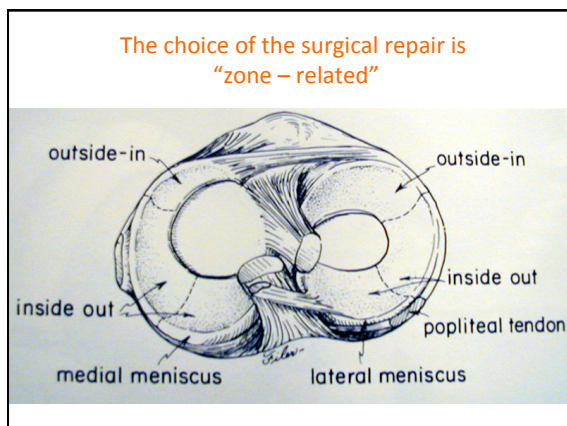
How I did

Inside-out suture

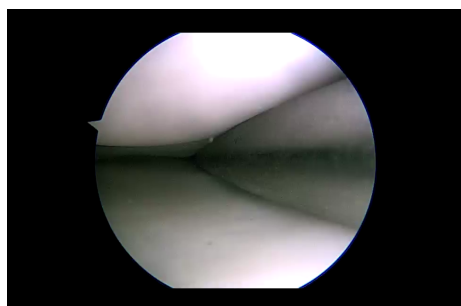
Now I do:

- All inside suture
 - for posterior horn and central third of the menisci
- Outside-in suture
 - for anterior horn of the menisci
- Rarely the inside-out suture
 - for meniscal substitution
 - For bucket handle tears

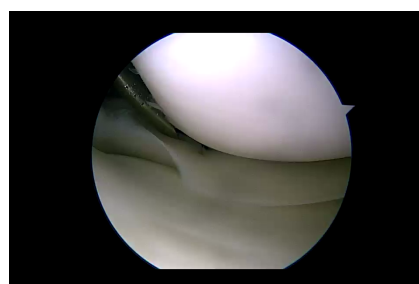




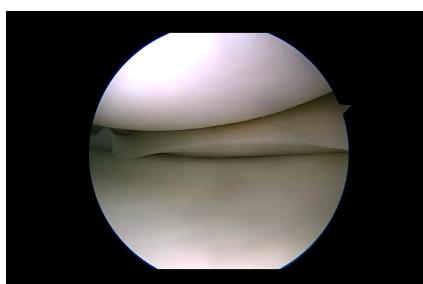
Freshening the tear site by rasping



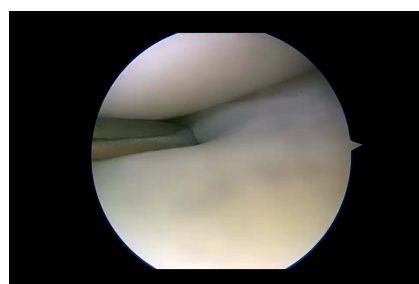
Superior passing



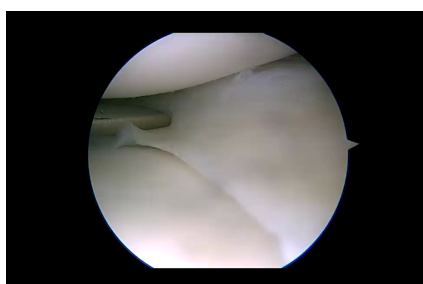
Inferior passing



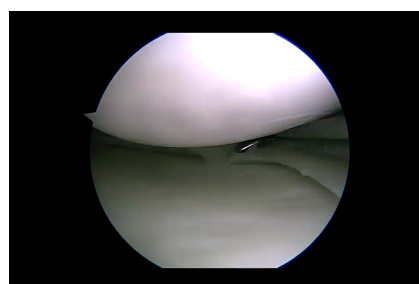
Superior passing



Inferior passing

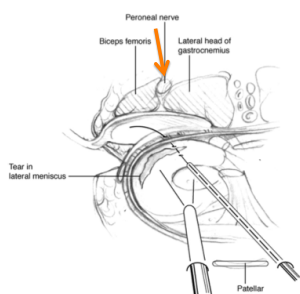


Final check



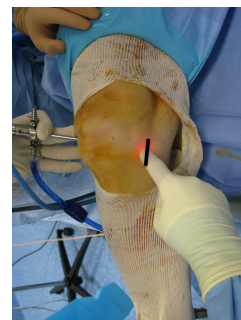Lateral Meniscus

- Figure-of-4 position (Cabot)
- Scope lateral cannula medial
- Posterolateral incision



Posterolateral incision

- Just behind the lateral collateral ligament
- The incision should be 2/3 below the joint line
- The ilio-tibial band is divided or retracted anteriorly
- Palpation of the muscle
- Retractor posteriorly to protect the peroneal nerve



ADVANTAGES

- Proven efficacy
- Cost-effective
- No devices
- Strength and compression (vertical sutures)
- Easier for bucket handle compared to all-inside sutures

DISADVANTAGES

- Associated mini-open procedure
- Potential neurovascular complications
- Time consuming
- Significant learning curve